Psychiatry Research Case Reports 5 (2026) 100306

Contents lists available at ScienceDirect

Psychiatry Research Case Reports

journal homepage: www.elsevier.com/locate/psycr

Remission of auditory verbal hallucinations following neuronavigated, personalized rTMS guided by EEG, MRI, and auditory evoked potentials: A case report

Barbora Provaznikova [a,*], Anna Monn [a], Aygün Ertuğrul [b], Samantha Weber [a], Erich Seifritz [a], Johannes Jungwirth [a], Golo Kronenberg [a], Sebastian Olbrich [a], Tobias Welt [a,*]

[a] Department of Adult Psychiatry and Psychotherapy, Psychiatric University Hospital Zurich CH-8032, Zurich, Switzerland
[b] Hacettepe University, Research Information System, Ankara, Türkiye

ARTICLE INFO

Keywords:
Auditory verbal hallucinations
Repetitive transcranial magnetic stimulation
EEG
sLORETA
MRI

ABSTRACT

Auditory verbal hallucinations (AVH) are a particularly distressing symptom of schizophrenia and are associated with significant reductions in quality of life. Antipsychotic medications fail to produce adequate symptom relief in approximately 25–30 % of patients and are frequently accompanied by adverse side effects, underscoring the need for effective alternative treatment. Repetitive transcranial magnetic stimulation (rTMS) has emerged as a non-invasive intervention for patients experiencing persistent AVH. While previous studies have explored the effects of rTMS on AVH, this is the first case report, to our knowledge, that combines individual localization of the primary auditory cortex using acoustic evoked potentials (AEP) and precise MRI-based neuronavigation for targeted rTMS application. The changes in auditory hallucinations were assessed through questionnaires and EEG (Electroencephalography), with standardized Low Resolution Brain Electromagnetic Tomography Analysis (sLORETA) used to investigate alterations in functional brain connectivity. We present the case of a 53-year-old male patient with schizoaffective disorder and persistent AVH, in whom AEP and MRI-based neuronavigation were combined to guide individualized rTMS targeting of the left primary auditory cortex. This personalized approach resulted in a rapid and complete remission of AVH after 5 days of rTMS treatment with 1 Hz Protocol. Notably, the clinical improvement was mirrored in source-localized EEG data using sLORETA, which showed reduced activity in the left parietal lobe (Brodmann area 40, postcentral gyrus) across higher frequency bands (Beta and Gamma). This could reflect a downstream or network-level modulation related to auditory processing and AVH symptoms. Further studies are needed to investigate the reproducibility of this approach.

Introduction

Auditory verbal hallucinations (AVH) are a highly distressing symptom of schizophrenia spectrum disorders that often reduce quality of life and are associated with increased risk of suicidality (Hor and Taylor, 2010). Antipsychotics are ineffective for 25 - 30 % of patients (Shergill et al., 1998) and commonly cause side effects (Leucht et al., 2009), underscoring the need for alternative treatments. AVH are linked to heightened activity in the primary and secondary auditory cortices, Wernicke's area in the superior temporal gyrus (STG), and Heschl's gyrus, predominantly in the left hemisphere. This has led repetitive transcranial magnetic stimulation (rTMS) studies to focus on these regions as key targets for intervention. Most sham-controlled studies focus on low-frequency rTMS (LF-rTMS) protocols (0.5 - 1 Hz) targeting the left temporoparietal cortex (TPC), including the superior temporal gyrus (STG) and temporoparietal junction (TPJ) (Lefaucheur et al., 2020). These studies yield mixed results – meta-analyses suggest a small-to-moderate effect size in favor of LF-rTMS at the left TPJ (Level C evidence), despite increasing placebo effects over time (He et al., 2017; Slotema et al., 2014). In contrast, high frequency (e.g., 20 Hz or theta-burst) over temporoparietal targets has also shown promise in some trials but with mixed results across studies (Dollfus et al., 2018; Ye et al., 2024).

Due to longstanding concerns regarding the limited precision in

* Corresponding authors at: Department of Adult Psychiatry and Psychotherapy, Psychiatric University Hospital Zurich, Lenggstrasse 31 CH-8032, Zurich, Switzerland.

E-mail addresses: barbora.provaznikova@pukzh.ch (B. Provaznikova), tobias.welt@pukzh.ch (T. Welt).

https://doi.org/10.1016/j.psycr.2025.100306
Received 25 July 2025; Received in revised form 17 November 2025; Accepted 7 December 2025
Available online 8 December 2025
2773-0212/© 2025 The Author(s). Published by Elsevier B.V. This is an open access article under the CC BY license (http://creativecommons.org/licenses/by/4.0/).

targeting this brain region, many researchers underscore the importance of neuronavigation. While multimodal studies combining TMS and fMRI have provided evidence of involvement of local speech-related and distal networks on stimulation of the left temporoparietal cortex, current evidence does not suggest the superiority of fMRI based neuronavigation over conventional methods for targeting. (SP Baliga and Mehta, 2021). As researchers increasingly attribute limited treatment effects to imprecise targeting, efforts are underway to improve the precision and effectiveness of neuronavigation techniques. A randomized controlled study used Dynamic Causal Modeling (DCM) in fMRI to investigate and localize the left temporoparietal junction (TPJ) in patients with schizophrenia experiencing AVH, revealing significant rTMS-induced changes in effective connectivity that were associated with clinical improvement (Yuanjun et al., 2024). An alternative, more cost-efficient approach could involve the use of EEG to support individualized targeting. A recent study found that inhibitory rTMS not only reduced AVH but also altered brain connectivity, decreasing aberrant beta-band synchronization and enhancing alpha-2 connectivity in language-related areas such as Wernicke's and Broca's regions. (Gornerova et al., 2023) standardized Low Resolution Brain Electromagnetic Tomography Analysis (sLORETA) is an advanced EEG source-localization technique that estimates three-dimensional current density distributions across the brain from scalp-recorded signals. It identifies the "smoothest" solution by assuming adjacent neurons activate simultaneously, offering a blurred—but physiologically meaningful—map of neural activity (Pascual-Marqui et al., 1994). When combined with acoustic evoked potentials (AEPs)—time-locked EEG responses to auditory stimuli—sLORETA enables the localization of cortical generators of specific auditory components (e.g., N100, P300). This allows researchers to track changes in current density within the auditory cortex (and associated networks), providing insight into cortical excitability and connectivity in response to treatment or disease (Gabr, 2024).

This case report describes a patient with AVH where AEPs and MRI-based neuronavigation were combined to guide individualized rTMS targeting of the primary auditory cortex. This personalized approach led to a rapid and complete, acute remission of AVH in a patient with a 40-year history of difficult-to-treat symptoms. The therapeutic response was accompanied by significant functional improvement, a reduction in the required dosage of antipsychotic medication, and enhanced adherence to outpatient treatment.

Case presentation

Mr. C., a 53-year-old male with a diagnosis of schizoaffective disorder, was admitted in March 2025 due to persistent auditory hallucinations and worsening depressive symptoms. He has experienced auditory hallucinations since childhood, most notably a male voice that he currently perceives as angry, critical, and at times commanding him to engage in self-harm. His thought processes appeared inhibited, ruminative, and intermittently disrupted. In addition to AVH, he exhibited further psychotic features, including tactile hallucinations (the sensation of cockroaches crawling on his skin) and somatic delusions (the belief that his left arm did not belong to him). He also described episodes of a sense of ominous significance, delusional beliefs of being impaired or defective, and persecutory ideas—for example, believing he would be arrested whenever he saw a police car. His thinking was marked by mistrust and a pervasive sense of being watched or followed. Alongside these psychotic symptoms, Mr. C. reported a range of depressive symptoms, including low drive, fatigue, anhedonia, social withdrawal, and persistent feelings of depression and anxiety. He also described pronounced feelings of inadequacy and guilt, severe sleep disturbances, and suicidal ideation, including episodes of watching YouTube videos about crematoriums, although he clearly stated he had no intention to act on these thoughts. His current medication regimen included Quetiapine 800 mg/d and Escitalopram 40 mg/d. According to his report, he had been taking quetiapine at a dose of 1000 mg/d from 2012 until 2024, when the dose was reduced to 800mg/d. He was subsequently switched to risperidone, which he discontinued due to what he described as an "allergy" or intolerance, although no further medical details are available. He then received olanzapine at a dose of 15 mg/d for approximately one month; a planned dose increase was not implemented. In terms of medical history, he was diagnosed with alcohol use disorder in 2024 related to problematic drinking behaviors that began in 2022. He completed inpatient rehabilitation in November 2024 and has remained abstinent from alcohol since then. He did not have any other medical or neurological disorders. Mr. C. is of Israeli origin and has lived in Switzerland for many years. Given the patient's extensive history with antipsychotic medications, he developed the belief that his auditory verbal hallucinations were intractable. This led to a reluctance to consider further pharmacological adjustments. As a result, the focus shifted toward exploring alternative treatments, with neuronavigated rTMS considered a suitable option. Electroconvulsive therapy was discussed as a therapeutic option for depressive and suicidal symptoms, and after informed counseling, the patient declined it. Clinically, we prioritized neuronavigated rTMS given his refractory AVH and preference. The patient was thoroughly informed about the potential risks and side effects of rTMS and gave informed consent. To define the individualized rTMS stimulation target, we recorded AEPs in response to 151 identical tone stimuli during a 64-channel EEG. Data were preprocessed in BrainVision Analyzer and further analyzed in Brainstorm, including band-pass filtering (0.1–30 Hz), epoching, and baseline correction (−100 ms to – 0.1 ms). Following noise covariance estimation and averaging, source localization was performed using sLORETA. The peak activation during the N100 component – corresponding to early auditory cortical processing – was localized within the left primary auditory cortex. These individualized coordinates were extracted from Brainstorm and imported into the ANT Neuro Visor2 neuronavigation system, where the stimulation target was visualized and registered on the patient's structural MRI. Using this approach, the figure-of-eight coil was precisely navigated to the functionally defined target region for inhibitory 1 Hz rTMS, with Visor 2 enabling real-time display of the projected stimulation field.

The visualisation of the target region is shown in Fig. 1.

This functionally defined region was then registered in the neuronavigation system as the target site for rTMS treatment, localized in the left primary auditory cortex and registered to MRI for neuronavigation. Using this visualization, the target location was marked by positioning the stimulation coil on an rTMS-cap aligned with the identified coordinates. rTMS was subsequently administered at this site using a 1 Hz stimulation protocol, delivering 2400 pulses per session over five consecutive days. Stimulation intensity was set at 100 % of the motor threshold. A 1 Hz protocol was chosen given its inhibitory profile and its historical use in AVH with small to moderate benefits and favorable tolerability. Mr. C. reported that the auditory hallucinations began to fade during the very first rTMS session and disappeared shortly thereafter. He expressed strong motivation to continue the treatment and reported, visibly moved, that for the first time in over 40 years, he no longer heard any voices.

AVH severity was assessed pre and post rTMS treatment with the Auditory Verbal Hallucination Rating Scale (AVHRS) and the Psychotic Symptom Rating Scales (PSYRATS) hallucination subscale; scores improved from 42→5 and 28→0, respectively, immediately posttreatment, with a delusions subscale decrease from 16→2. (Bartels-Velthuis et al., 2012; Haddock et al., 1999; Steenhuis et al., 2019; Wahab et al., 2015) The time points of the symptom assessments as well as the corresponding rating scale scores are presented in Fig. 1.

Source estimate computation and statistics

EEG-source estimation has been performed using the exact low resolution electromagnetic tomography (Pascual-Marqui et al., 2011) software, as provided by Roberto Pascual-Marqui/The KEY Institute for

A. AEPs on 3D brain

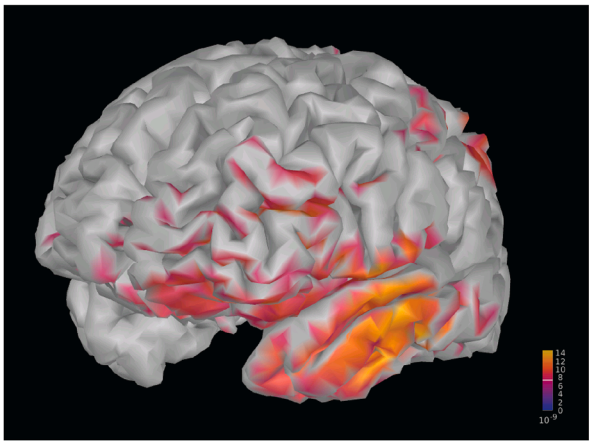

B. Brain response 50 to 600 ms after AEPs

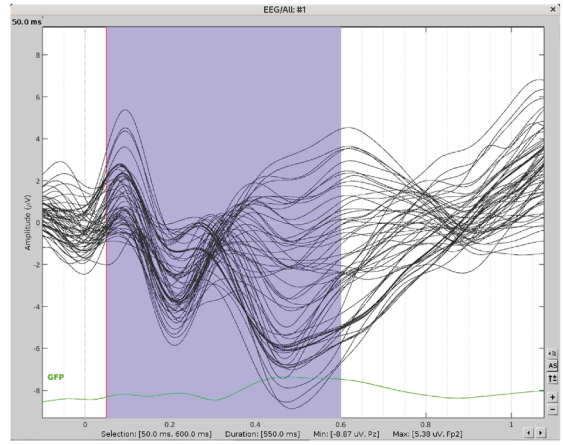

C. Timeline of the rTMS treatment

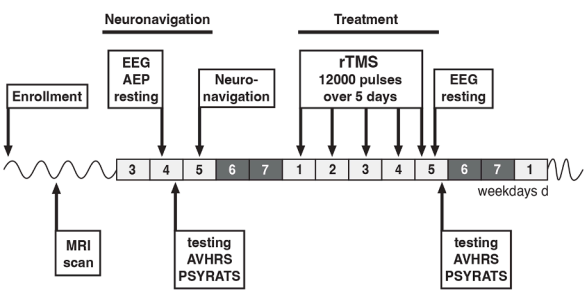

D. Results of AVHRS

AVHRS No.	Question	pre rTMS	post rTMS
1a	Number of voices	1	0
1b	Seperate or simultaneously	1	0
2	Hypnagogic and/or hypnopompic	4	0
3	Frequency	2	0
4	Duration	2	0
5	Location	3	3
6	Loudness	2	0
7	Origin of voices	2	2
8	Negative content	3	0
9	Severity of negative content	4	0
10	Frequency of distress or suffering	3	0
11	Intensity of distress or suffering	3	0
12	Interference with daily functioning	2	0
13	Control	3	0
14	Anxiety	3	0
15	Interference with thinking	3	0
16	1st, 2nd or 3rd person voices	1	0
	Total	**42**	**5**

E. Results of PSYRATS - Subsection Hallucinations

PSYRATS - Auditory hallucinations No.	Question	pre rTMS	post rTMS
1	Frequency	2	0
2	Duration	2	0
3	Location	2	0
4	Loudness	2	0
5	Beliefs re-origin of voices	2	0
6	Amount of negative content	2	0
7	Degree of negative content	4	0
8	Amount of distress	3	0
9	Intensity of distress	3	0
10	Disruption of life caused by voices	2	0
11	Controllability of voices	3	0
	Total	**27**	**0**

F. Results of PSYRATS - Subsection Delusions

PSYRATS Delusions No.	Question	pre rTMS	post rTMS
1	Amount of preoccupation with delusions	2	0
2	Duration of preoccupation with delusions	1	0
3	Conviction	4	0
4	Amount of distress	4	0
5	Intensity of distress	3	1
6	Disruption to life caused by beliefs	3	1
	Total	**17**	**2**

Fig. 1. **A.** Source-localized EEG activity following auditory evoked potentials (AEPs), projected onto a 3D brain model based on the patient's individual MRI. **B.** Time course of brain responses from 50 to 600 ms after AEP stimulation. **C.** Timeline of the rTMS treatment protocol including MRI acquisition, EEG recordings (resting state and auditory evoked potentials), functional neuronavigation, and treatment sessions (1 Hz inhibitory rTMS, 2400 pulses per day, 12,000 pulses over five days). Clinical assessments (AVHRS, PSYRATS) were conducted before and after the intervention. **D.** Results of the AVHRS questionnaire before and after rTMS treatment, showing a reduction in total score from 42 to 5 points. E. Item-level results of the PSYRATS subsection "Auditory Hallucinations" (pre: 27; post: 0). F. Item-level results of the PSYRATS subsection "Delusions" (pre: 17; post: 2).

Brain-Mind Research University Hospital of Psychiatry, Zurich (Pascual-Marqui et al., 2018a, 2018b, 2017a, 2017b, 2017c). The sLORETA algorithm is a linear inverse solution for EEG signals (Pascual-Marqui et al., 2002). EEG power source estimates were computed using sLORETA for the EEG alpha (8–12 Hz), beta 1 (12.5–20 Hz), beta 2 (20.5–30 Hz), delta (1–3.5 Hz) and theta (4–7.5 Hz) frequency bands.

Statistical analysis has been performed using the statistics module of the sLORETA software package (2022/12/29). The methodology used was non-parametric. It was based on estimating, via randomization, the empirical probability distribution for the maximum of a F-statistic, under the null hypothesis. Due to the non-parametric nature of the method, its validity did not need to rely on any assumption of Gaussianity (Nichols and Holmes, 2002). The signal to noise ratio defined as the ratio between power of each analysed frequency band and the sum of the power of all remaining frequency bands for all EEG-channels was computed. EEG-source estimates from the five frequency bands delta, theta, alpha, beta 1 and beta 2 were compared between the conditions using F-statistics. A correction for multiple comparisons was applied (Nichols and Holmes, 2002) for the collection of tests performed (derived from the number of 6239 voxels of the intracortical solution space and the number of five distinct frequency bands).

EEG and sLORETA results

Source-localized EEG data provided further support for the clinical response. Resting-state EEG was recorded before and after the rTMS intervention, showing a significant post-stimulation reduction in beta and gamma band activity (Beta 1: 12.5–20 Hz, Beta 2: 20.5–30 Hz, Gamma 1: 30.5–50 Hz, Gamma 2: 50.5–100 Hz), localized to Brodmann area 40 (postcentral gyrus, left parietal lobe) at coordinates $X=-55$, $Y=-25$, $Z = 15$. Greater activity in this region prior to stimulation is indicated by red color coding in Fig. 2, corresponding to a reduction in neural activity following treatment ($p < 0.05$, Bonferroni corrected).

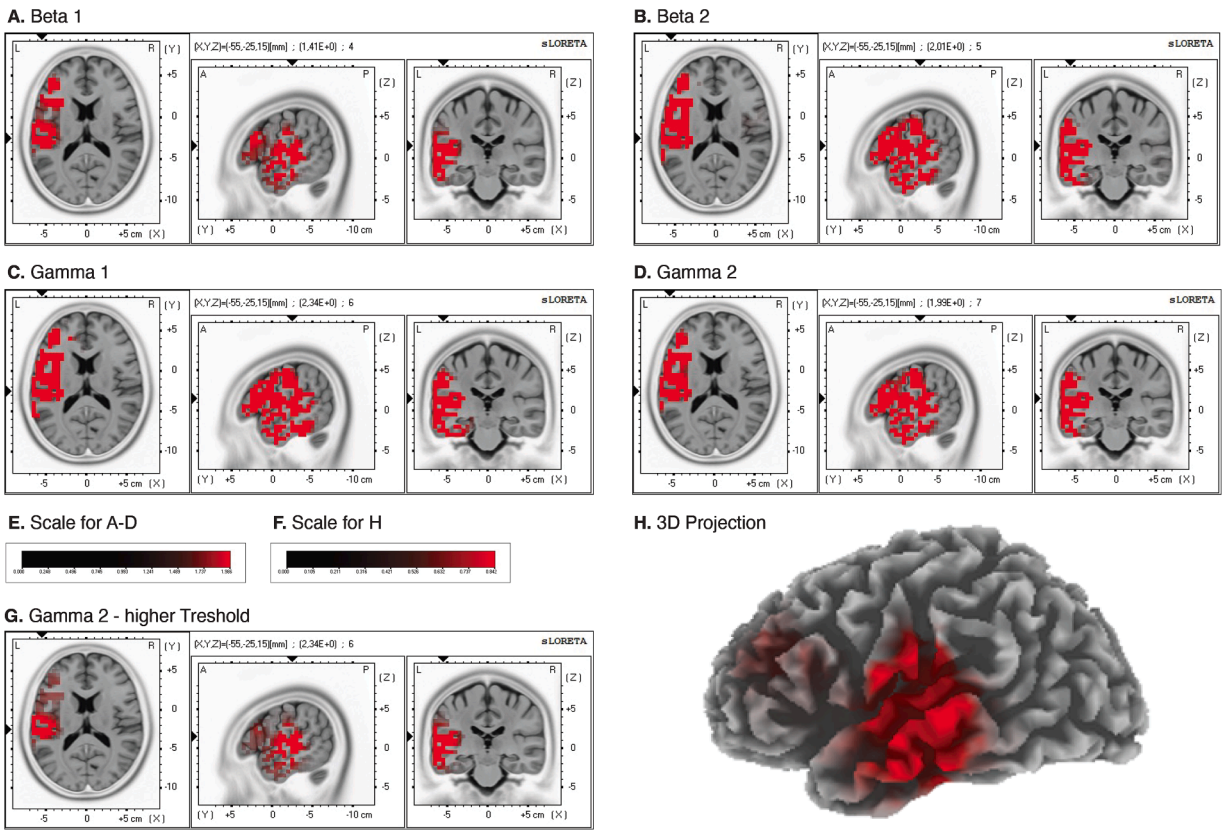

Fig. 2. Reduction of beta and gamma band activity as measured by resting-state EEG, comparing post- versus pre-rTMS treatment. The best match is observed at 0 mm in Brodmann area 40, encompassing the postcentral gyrus and parietal lobe. A consistent reduction in EEG activity within regions associated with speech processing is evident across multiple frequency bands: **A.** Beta 1 band (value= 1.41E + 0, MNI coordinates $x = -55$ $Y = -25$ $Z = 15$), **B.** Beta 2 band (value= 2.01E + 0, MNI coordinates $x = -55$ $Y = -25$, $Z = 15$) **C.** Gamma 1 band (value= 2.01E + 0 MNI coordinates $x = -55$ $Y = -25$ $Z = 15$), and **D.** Gamma 2 band (value = 1.99E+0, MNI coordinates $X = -55$ $Y = -25$ $Z = 15$) . using the threshold scale shown in **E.** Applying a higher threshold **(F)** further highlights the reduction in Gamma 2 activity, especially within cortical areas involved in speech comprehension, as illustrated across all three anatomical planes **(G)** and in the 3D projection based on the patient's individual MRI scan **(H)**.

Although the stimulation targeted the primary auditory cortex, this parietal region is functionally connected and involved in auditory processing and sensory integration, which may explain its role in the observed symptom resolution.

Mr. C. was also pleased to revise his medication regimen, which had previously not been a viable option. Quetiapine was successfully tapered from 800 mg/day to zero, and he agreed to initiate treatment with aripiprazole. The off-label dosage of escitalopram 40mg/d was reduced to the recommended 20 mg/d. No medication changes were initiated during the 5 day rTMS course; pharmacologic adjustments commenced after completion of the acute rTMS sessions. The improvement in auditory hallucinations also had a positive impact on his depressive symptoms. While some residual symptoms persisted — such as reduced concentration, low self-esteem, and diminished drive — there were no indications of perceptual disturbances or delusional thinking, and his mood improved. Mr. C. demonstrated a renewed sense of purpose: he was preparing to start a new job, actively applying for various positions, and showed good adherence to the outpatient therapy plan we proposed. Later follow-up revealed that symptom remission lasted for approximately one month. The patient reported that the auditory hallucinations returned after this period and subsequently sought readmission, specifically requesting another course of rTMS, consisting of 5 rTMS sessions with the same parameters. Following the acute course, a pragmatic maintenance schedule was initiated (once weekly for 4 sessions). When the interval was increased to every other week, the patient discontinued attendance and maintenance was not continued under community care. At last contact, he reported that AVH were 'manageable,' without further acute interventions.

Discussion

This case report introduces a novel approach by combining MRI-guided neuronavigation with EEG and LORETA to precisely target hyperactive speech-processing regions, aiming to enhance rTMS effectiveness for AVH. Using this individualized method, a rapid remission of AVH was observed in this patient, accompanied by a normalization of previously hyperactive acoustic evoked potentials. If supported by further evidence from randomised controlled studies, this method could offer a valuable complement or alternative to antipsychotic medication, contributing to more precise and individualized psychiatric treatment.

It remains unclear whether similar effects could be achieved without neuronavigation. In a sham-controlled trial, MRI-guided rTMS of the left superior temporal sulcus significantly reduced auditory hallucinations, suggesting the value of precise targeting - though high-frequency (20 Hz) stimulation was used - contrary to common low-frequency protocols (Dollfus et al., 2018). Another small crossover study ($n = 16$) found that low-frequency (1 Hz) neuronavigated rTMS of Broca's area induced more precise and effective stimulation than conventional methods (Kim et al., 2014). However, both studies relied solely on MRI-based navigation without integrating EEG data.

Several discussion points arise from this case report. It is difficult to differentiate whether the observed improvements reflect a genuine neuromodulatory effect of rTMS or are better explained by a placebo response. The potential for a placebo effect must be considered,

particularly considering evidence from a meta-analysis of 21 sham-controlled rTMS trials for auditory hallucinations in schizophrenia, which reported a small but statistically significant placebo effect (Hedges' $g = 0.29$). Interestingly, the magnitude of the placebo response varied considerably depending on study design and the type of sham stimulation used (Dollfus et al., 2016). Therefore, this single-case report cannot establish causality or support generalization. The rapid improvement may reflect, in part, non-specific factors (e.g., expectancy/placebo) and concurrent clinical care. However, in our case, the changes observed in the sLORETA analysis following rTMS treatment support the conclusion that the clinical improvement reflects a genuine neuromodulatory effect of rTMS. The targeted area—the left auditory cortex—and functionally connected parietal regions, particularly Brodmann Area 40 in the parietal lobe, showed significant post-stimulation reductions in beta and gamma band activity. Prior rTMS work in AVH has reported network level modulation within temporoparietal language circuits alongside symptom change, including alterations in oscillatory dynamics and functional connectivity, supporting a distributed rather than purely focal effect (Gornerova et al., 2023; Zhang et al., 2025). In this context, the BA40 beta/gamma decrease can be viewed as a downstream network signature of targeting the left auditory cortex/TPJ. Nonetheless, single-case EEG cannot establish mechanism; these findings should be considered convergent and hypothesis generating.

While EEG findings converge with symptom change, such measures can vary independently of clinical response, and single case designs can not ascribe mechanism. The rapid onset of improvement — within the first session — appears atypical and may reflect expectancy/placebo effects, spontaneous fluctuation, or statedependent susceptibility of the targeted network.

Symptom remission lasted for one month following treatment. This real world attempt at maintenance underscores that durability may depend on adherence, clinician support, and scheduling feasibility; while the patient ultimately rated AVH as 'manageable,' structured, prospectively defined maintenance and adherence supports are likely important for sustaining remission. A pragmatic maintenance approach could include tapering schedules (e.g., weekly for 4–6 weeks, then biweekly, then monthly), fixedinterval boosters (e.g., 1–2 sessions every 2–4 weeks), or symptom-triggered boosters. Despite the chronic nature of AVH, no published protocols currently address maintenance rTMS for this condition. While rTMS can reduce symptom-related cortical activity temporarily, sustained effects may require repeated sessions. Though AVH-specific data are limited, studies in depression suggest that maintenance rTMS — especially when administered more than twice per month — can reduce relapse risk, with vulnerability peaking around five months post-treatment (d'Andrea et al., 2023).

EEG/AEP-guided targeting appears to be a practical, cost-effective bedside approach that offers millisecond temporal resolution linked to stimulus-locked auditory components (e.g., N100), thereby allowing physiology-informed, real-time targeting. In contrast, fMRI-guided TMS provides higher spatial precision and facilitates whole-brain network mapping, although its use may be constrained by access and cost (SP Baliga and Mehta, 2021). A pragmatic approach is to use EEG/AEP when feasibility and speed are paramount, reserving fMRI for complex or refractory cases; hybrid EEG–fMRI workflows merit head to head evaluation with implementation and cost-effectiveness endpoints.

Further research is needed to evaluate the efficacy, optimal parameters, and maintenance strategies of this combined targeting approach. This case adds to the growing body of evidence suggesting that anatomically and functionally precise rTMS may improve outcomes for patients with treatment-resistant AVH, and it highlights the importance of continued innovation in neuromodulatory psychiatry.

CRediT authorship contribution statement

Barbora Provaznikova: Writing – original draft. **Anna Monn:** Data curation. **Aygün Ertuğrul:** Writing – review & editing. **Samantha Weber:** Data curation. **Erich Seifritz:** Supervision. **Johannes Jungwirth:** Supervision. **Golo Kronenberg:** Supervision. **Sebastian Olbrich:** Writing – review & editing, Supervision, Data curation. **Tobias Welt:** Writing – review & editing, Visualization, Supervision, Data curation, Conceptualization.

Declaration of competing interest

All authors declare that there is no conflict of interest.

References

Baliga, S.P., Mehta, U.M., 2021a. A review of studies leveraging multimodal TMS-fMRI applications in the pathophysiology and treatment of schizophrenia. Front. Hum. Neurosci. 15, 662976.

Baliga, S.P., Mehta, U.M., 2021b. A review of studies leveraging multimodal TMS-fMRI applications in the pathophysiology and treatment of schizophrenia. Front. Hum. Neurosci. 15, 662976.

Bartels-Velthuis, A.A., van de Willige, G., Jenner, J.A., Wiersma, D., 2012. Consistency and reliability of the auditory vocal hallucination rating scale (AVHRS). Epidemiol. Psychiatr. Sci. 21 (3), 305–310. Sept.

d'Andrea, G., Mancusi, G., Santovito, M.C., Marrangone, C., Martino, F., Santorelli, M., et al., 2023. Investigating the role of maintenance TMS protocols for major depression: systematic review and future perspectives for personalized interventions. J. Pers. Med. 13 (4), 697. Apr 21.

Dollfus, S., Jaafari, N., Guillin, O., Trojak, B., Plaze, M., Saba, G., et al., 2018. High-frequency neuronavigated rTMS in auditory verbal hallucinations: a pilot double-blind controlled study in patients with schizophrenia. Schizophr. Bull. 44 (3), 505–514. Apr.

Dollfus, S., Lecardeur, L., Morello, R., Etard, O., 2016. Placebo response in repetitive transcranial magnetic stimulation trials of treatment of auditory hallucinations in schizophrenia: a meta-analysis. Schizophr. Bull. 42 (2), 301–308. Mar.

Gabr, T., 2024. Auditory evoked potentials: objectives procedures in the assessment of cochlear implants outcomes. Egypt. J. Otolaryngol. 40 (1), 155. Nov 20.

Gornerova, N., Brunovsky, M., Klirova, M., Novak, T., Zaytseva, Y., Koprivova, J., et al., 2023. The effect of low-frequency rTMS on auditory hallucinations, EEG source localization and functional connectivity in schizophrenia. Neurosci. Lett. 794, 136977. Jan 18.

Haddock, G., McCarron, J., Tarrier, N., Faragher, E.B., 1999. Scales to measure dimensions of hallucinations and delusions: the psychotic symptom rating scales (PSYRATS). Psychol. Med. 29 (4), 879–889. July.

He, H., Lu, J., Yang, L., Zheng, J., Gao, F., Zhai, Y., et al., 2017. Repetitive transcranial magnetic stimulation for treating the symptoms of schizophrenia: a PRISMA compliant meta-analysis. Clin. Neurophysiol. 128 (5), 716–724. May.

Hor, K., Taylor, M., 2010. Suicide and schizophrenia: a systematic review of rates and risk factors. J. Psychopharmacol. 24 (4), 81–90. NovSuppl.

Kim, W.J., Min, Y.S., Yang, E.J., Paik, N.J., 2014. Neuronavigated vs. conventional repetitive transcranial magnetic stimulation method for virtual lesioning on the Broca's area. Neuromodulation 17 (1), 16–21. Jandiscussion 21.

Lefaucheur, J.P., Aleman, A., Baeken, C., Benninger, D.H., Brunelin, J., Di Lazzaro, V., et al., 2020. Evidence-based guidelines on the therapeutic use of repetitive transcranial magnetic stimulation (rTMS): an update (2014-2018). Clin. Neurophysiol. 131 (2), 474–528. Feb.

Leucht, S., Corves, C., Arbter, D., Engel, R.R., Li, C., Davis, J.M., 2009. Second-generation versus first-generation antipsychotic drugs for schizophrenia: a meta-analysis. Lancet 373 (9657), 31–41. Jan 3.

Nichols, T.E., Holmes, A.P., 2002. Nonparametric permutation tests for functional neuroimaging: a primer with examples. Hum. Brain Mapp. 15 (1), 1–25. Jan.

Pascual-Marqui, R., Faber, P., Ikeda, S., Ishii, R., Kinoshita, T., Kitaura, Y., et al., 2017a. The cross-frequency mediation mechanism of intracortical information transactions [Internet]. Neuroscience [cited 2025 Nov 4]. Available from: http://biorxiv.org/lookup/doi/10.1101/119362.

Pascual-Marqui, R.D., Biscay, R.J., Bosch-Bayard, J., Faber, P., Kinoshita, T., Kochi, K., et al., 2017b. Innovations orthogonalization: a solution to the major pitfalls of EEG/MEG "leakage correction" [Internet]. Neuroscience [cited 2025 Nov 4]. Available from: http://biorxiv.org/lookup/doi/10.1101/178657.

Pascual-Marqui, R.D., Biscay, R.J., Bosch-Bayard, J., Faber, P., Kinoshita, T., Kochi, K., et al., 2017c. Measures of time series coupling based on generalized weighted multiple regression [Internet]. Neuroscience [cited 2025 Nov 4]. Available from: http://biorxiv.org/lookup/doi/10.1101/235721.

Pascual-Marqui, R.D., Esslen, M., Kochi, K., Lehmann, D., 2002. Functional imaging with low-resolution brain electromagnetic tomography (LORETA): a review. Methods Find. Exp. Clin. Pharmacol. 24 (C), 91–95. Suppl.

Pascual-Marqui, R.D., Faber, P., Kinoshita, T., Kochi, K., Milz, P., Keiichiro, N., et al., 2018a. A comparison of bivariate frequency domain measures of electrophysiological connectivity [Internet]. Neuroscience [cited 2025 Nov 4]. Available from: http://biorxiv.org/lookup/doi/10.1101/459503.

Pascual-Marqui, R.D., Faber, P., Kinoshita, T., Kochi, K., Milz, P., Nishida, K., et al., 2018b. Comparing EEG/MEG neuroimaging methods based on localization error, false positive activity, and false positive connectivity [Internet]. Neuroscience [cited 2025 Nov 4]. Available from: http://biorxiv.org/lookup/doi/10.1101/269753.

Pascual-Marqui, R.D., Lehmann, D., Koukkou, M., Kochi, K., Anderer, P., Saletu, B., et al., 2011. Assessing interactions in the brain with exact low-resolution electromagnetic tomography. Philos. Trans. Math. Phys. Eng. Sci. 369 (1952), 3768–3784. Oct 13.

Pascual-Marqui, R.D., Michel, C.M., Lehmann, D., 1994. Low resolution electromagnetic tomography: a new method for localizing electrical activity in the brain. Int. J. Psychophysiol. 18 (1), 49–65. Oct.

Shergill, S.S., Murray, R.M., McGuire, P.K., 1998. Auditory hallucinations: a review of psychological treatments. Schizophr. Res. 32 (3), 137–150. Aug 17.

Slotema, C.W., Blom, J.D., van Lutterveld, R., Hoek, H.W., Sommer, I.E.C., 2014. Review of the efficacy of transcranial magnetic stimulation for auditory verbal hallucinations. Biol. Psychiatry 76 (2), 101–110. July 15.

Steenhuis, L.A., Pijnenborg, G.H.M., Visser, E., van de Willige, G., van Beilen, M., Nauta, M.H., et al., 2019. The development, validity, and reliability of the auditory vocal hallucination rating scale questionnaire (AVHRS-Q). Soc. Psychiatry Psychiatr. Epidemiol. 54 (8), 927–935. Aug.

Wahab, S., Zakaria, M.N., Sidek, D., Abdul Rahman, A.H., Shah, S.A., Abdul Wahab, N.A, 2015. Evaluation of auditory hallucinations in patients with schizophrenia: a validation study of the Malay version of psychotic symptom rating scales (PSYRATS). Psychiatry Res. 228 (3), 462–467. Aug 30.

Ye, S.Y., Chen, C.N., Wei, B., Zhan, J.Q., Li, Y.H., Zhang, C., et al., 2024. The efficacy and safety of continuous theta burst stimulation for auditory hallucinations: a systematic review and meta-analysis of randomized controlled trials. Front. Psychiatry 15, 1446849.

Yuanjun, X., Guan, M., Zhang, T., Ma, C., Wang, L., Lin, X., et al., 2024. Targeting auditory verbal hallucinations in schizophrenia: effective connectivity changes induced by low-frequency rTMS. Transl. Psychiatry 14, 393. Sept 28.

Zhang, L., Guo, L., Liu, X., Han, J., Zhu, Y., Ma, C., et al., 2025. Low-frequency rTMS modulates small-world network properties in an AVH-related brain network in schizophrenia. Front. Psychiatry 16, 1578072. Apr 15.